



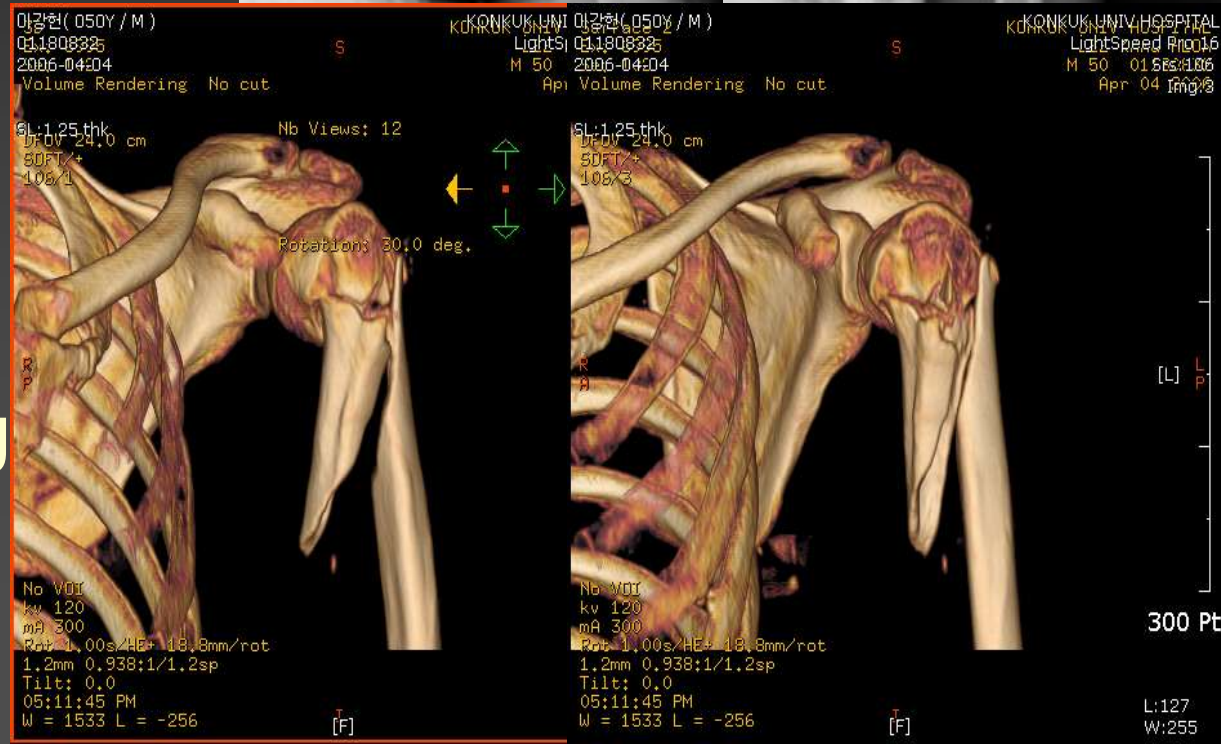
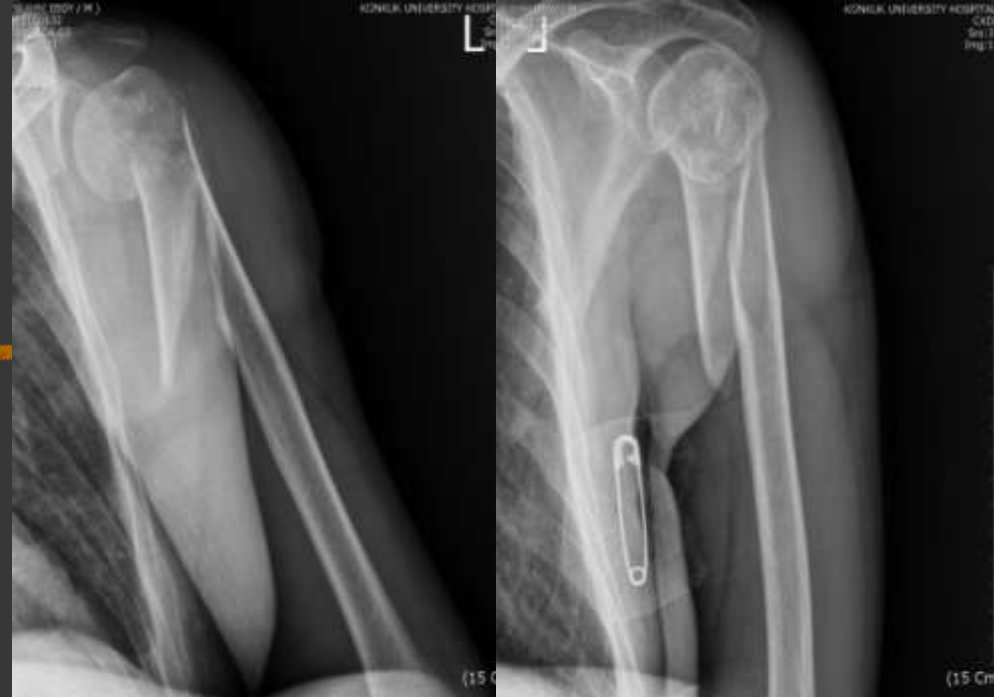# Case presentation Proximal Humerus

---

Jin-Young Park  
*Shoulder, Elbow & Sports Service  
Konkuk University Hospital,  
Seoul, Korea*

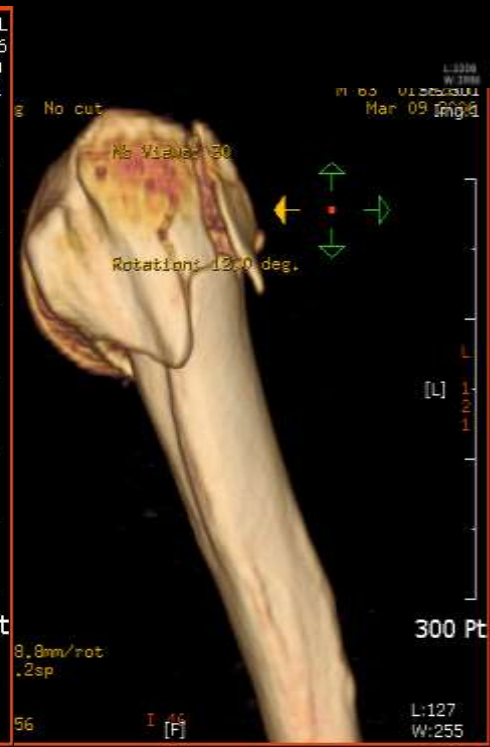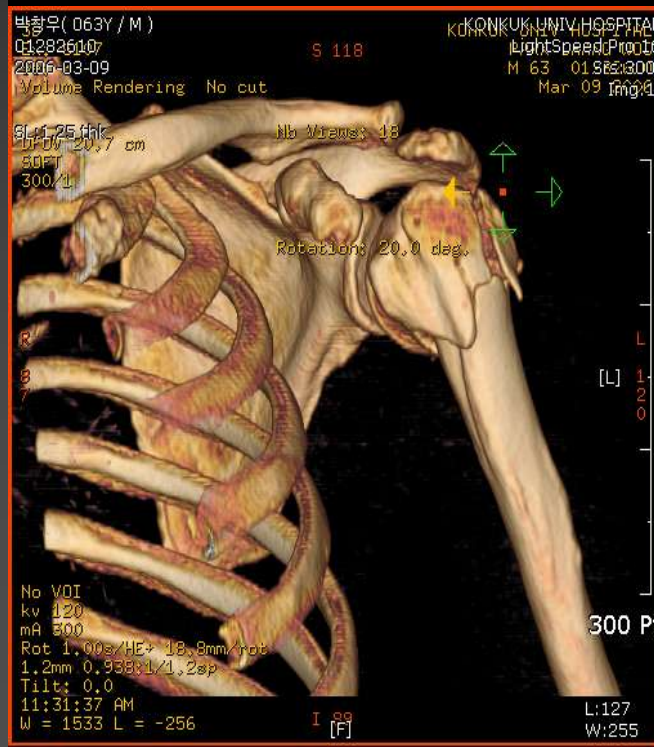
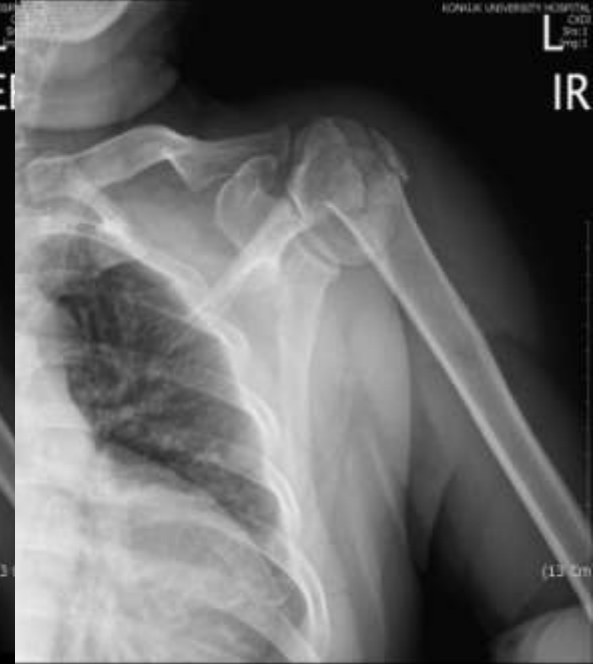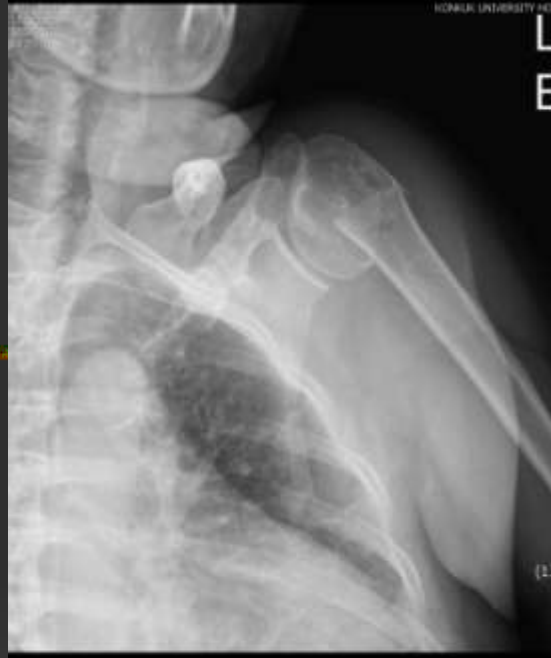# Case I.

- 50/M
- Driver TA
- Treatment ?
  - Conserv. Tx
  - Percutan. Pin
  - Closed nailing
  - Open plating
  - Open nailing



# Case II.

- 64/M
- Slip down injury



## ● Diagnosis ?

- 2 part SN Fx.
- 3 part SN+GT Fx
- 3 Part SN+LT Fx
- 4 part Fx.

# Case III.

- 41 / M
- Pedestrian TA
- 2 time op
  - CRPP
  - ORIF c/ BG
- Treatment Option?
  - Plating
  - Simple Nailing
  - Hot-Air Ballooning (HAB) technique
  - Humeral head replacement
  - Skillful neglect

